

## HEMIPENECTOMY IN LEOPARD GECKOS, CHAMELEONS AND BEARDED DRAGONS

Seven Mustafa<sup>1</sup>, Iliana Ruzhanova-Gospodinova<sup>2</sup>

*Faculty of Veterinary Medicine, University of Forestry, Sofia (Bulgaria)*

<sup>1</sup>*Department of Surgery, Radiology, Obstetrics, and Gynecology*

<sup>2</sup>*Department of Anatomy, Physiology, and Animal Science*

Corresponding e-mail: <sup>1</sup>[s.mustafa@ltu.bg](mailto:s.mustafa@ltu.bg) <sup>2</sup>[iliana\\_ruzhanova@ltu.bg](mailto:iliana_ruzhanova@ltu.bg)

### ABSTRACT

The purpose of the present study aims to describe 16 clinical cases of pet lizards with hemipenile prolapse – 11 leopard geckos (*Eublepharis macularius*), 3 chameleons (2 *Chamaeleo calypttratus* and 1 *Furcifer pardalis*), and 2 bearded dragons (*Pogona vitticeps*). After an unsuccessful attempt of manual repositioning of the everted hemipenes, unilateral or bilateral surgical amputation was performed to avoid future complications. All patients were anesthetized with a combination of medetomidine hydrochloride and ketamine hydrochloride. In the bearded dragons, a local block with lidocaine hydrochloride was additionally used. The authors' clinical experience with this surgical procedure confirmed the view that the hemipenectomy is an appropriate attempt in hemipenile prolapse in pet lizards from the Eublepharidae, Chamaeleonidae, and Agamidae families.

**Key words:** hemipenile prolapse, hemipenectomy, amputation, reptile, anesthesia

### INTRODUCTION

Reptiles have always attracted interest as unusual companion animals, but in the last few years, their number as pets has increased several times. Undoubtedly, leopard geckos and bearded dragons are the most widely bred reptiles due to their small size and ability to socialize easily with people (Valdez, 2021). Chameleons are not as common as the other two species, but they have always enjoyed the attention of terrarists. One of the most common diseases these pet lizards suffer from is related to the prolapse of various organs through the cloaca. In a case of a prolapse, it is important to identify the affected organ – if it consists entirely of everted cloacal tissue or colon, oviduct, hemipenis (or hemipenes) in snakes and lizards or penis in chelonians and crocodiles (Hedley & Eatwell, 2014).

Lizards have a pair of hemipenes caudal to the cloaca – blind-ended organs containing a wall of blood and lymph, located at the ventral base of the tail in an inverted position (Palmer et al., 1997). They are not involved in the urinary function (as reptiles lack penile urethra) but are strictly reproductive organs for semen transport, as only one hemipenis is used for insemination (Lock, 2000). The two major pairs of muscles controlling hemipenes function are the *m. transversus hemipenis*, which wraps around each hemipenis and mediates its eversion, and the *m. retractor hemipenis magnus* which attaches to the base of each hemipenis and retracts the organs after eversion (Holmes et al., 2005).

Hemipenile prolapse is established when the copulatory organ remains everted during a prolonged period. Desiccation and necrosis of the hemipenile tissue will occur if not promptly

relocated (Lescano & Quevedo, 2016). The substrate used, like peat and sand, may cause irritation and may worsen the condition of the patient (Innis & Boyer, 2002). Common causes of hemipenile prolapse are constipation or fecal impaction, nematode load, foreign body gastritis, diarrhea, hypocalcemia, nutritional secondary hyperparathyroidism, straining or tenesmus, chronic sexual activity, forced separation during copulation and secondary inflammation due to sex probing (Silva et al., 2013; Podhade & Harne, 2014). Spinal injury and neurogenic defects of the cloaca and muscles so as tearing of the retractor muscle, can also occur (Innis & Boyer, 2002; Martinez-Jimenez & Hernandez-Divers, 2007; Govindan et al., 2014).

The choice of approach in hemipenile prolapse depends on the duration and the degree of infection. If tissue edema is present in the absence of necrosis, the swelling could be reduced after soaking in a hypertonic solution followed by manual repositioning. A pressure bandage is recommended for preventing the protrusion of hemipenis (Vasaruchapong, 2014). If the prolapse was left untreated for a long period and infection or desiccation was present, surgical amputation should be considered (Di Girolamo & Mans, 2016). The same is required also if the manual repositioning is unsuccessful. Studies on the hemipenile morphology were performed by various researchers in Bulgaria (Andonov et al., 2017; Vergilov et al., 2017) and the procedure of the surgical removal of the hemipenes was described by Chaprazov (2022).

This study aims to describe the successful surgical treatment of hemipenile prolapse under general anesthesia in 16 pet lizard patients in the period of 2022-2023 in Bulgaria.

**MATERIALS AND METHODS**

Sixteen pet lizards with hemipenile prolapse were included in the study, all of them kept in terrarium conditions, between 2 and 4 years old. The type of prolapse by lizard species is presented in Table 1.

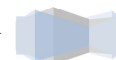**Table 1: Number of patients for the period of 2022-2023.**

Species	Unilateral hemipenile prolapse	Bilateral hemipenile prolapse	Total number of patients
Leopard gecko ( <i>Eublepharis macularius</i> )	4*	7	11
Veiled chameleon ( <i>Chamaeleo calypttratus</i> )	--	2	2
Panther chameleon ( <i>Furcifer pardalis</i> )	--	1	1
Bearded dragon ( <i>Pogona vitticeps</i> )	--	2	2

\*One with necrosis of the hemipenile bulge.

***Terrarium conditions and diet***

Three of the leopard geckos were kept on kitchen paper (two with unilaterally prolapsed hemipenes and one with bilateral), and all the other geckos – on a sand mixture. Eight of them were heated with heating pads under the terrariums. The rest were kept on room temperature. The leopard geckos were fed up mainly with mealworms.

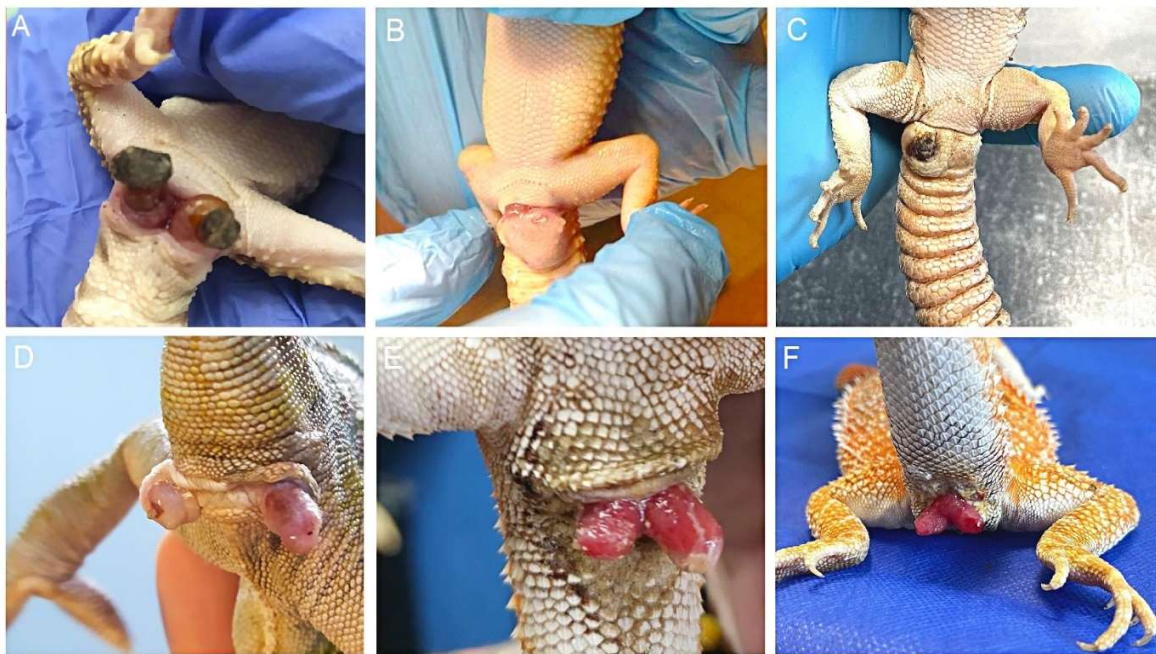


The chameleons were kept in vertical terrariums with coconut substrate on the floor. The heating was ensured by combined light/heat bulb kit, providing also UV-B lightning. They were fed up with domestic crickets.

The bearded dragons were grown on a sand mixture. The heating was ensured by heating spot lamps. A standart fluorescent tube was used for the UV-B lightning needs. The diet of the bearded dragons included domestic crickets and cockroaches but no vegetables.

### ***Conventional therapy***

In all cases, manual repositioning of the prolapsed tissues was initially attempted after presoaking in 20% Dextrose solution and injection of dexamethasone (Dexamethasonic®, Vet Prom) in a dose of 1 mg/kg. Only one of the bearded dragons showed a temporary result, but one day later the hemipenes prolapsed again. After the unsuccessful attempts for manual repositioning of the clinically presented prolapses (Fig. 1), surgical removal was suggested. In one of the cases in the leopard geckos no prolapsed hemipenis was observed, but only infection and necrosis at the base of the hemipenile bulge were established (Fig. 1-C), so the same surgical procedure was performed, according to Funk (2002).



**Figure 1: Hemipenile prolapses established in the pet lizard patients.**

A – bilateral hemipenile prolapse in leopard gecko with desiccation; B – hemipenile prolapse with abscessation in leopard gecko; C – necrosis of the hemipenile bulge in a leopard gecko; D – bilateral hemipenile prolapse in a veiled chameleon; E-F – bilateral hemipenile prolapse in a bearded dragon;

### ***Anesthetic protocol***

The patients were anesthetized with a combination of *ketamine hydrochloride* (Anaket®, Richter Pharma) and *medetomidine hydrochloride* (Domitor Vet®, Orion Pharma) administered intramuscularly. The doses used were respectively 5 mg/kg + 0,15 mg/kg for the geckos and

chameleons, and 10 mg/kg + 0,3 mg/kg for the bearded dragons. On the last a local block was performed at the base of the hemipenes with 2% lidocaine hydrochloride 4 mg/kg (Lidocain®, Sopharma). The reverse agent *atipamezole hydrochloride* (Antisedan®, Orion Pharma) was used in case of need in a dose 5 times higher than the medetomidine one, injected intramuscularly.

### ***Surgical procedure***

The leopard geckos and bearded dragons were placed in the dorsal recumbency position (Fig. 2-A), while the chameleons were placed in lateral recumbency. Surgical antisepsis on the cloacal area was performed using 0,2% chlorhexidine solution. Hemipenes were fixed and stretched separately. Transfixing ligature was placed at the base of the affected hemipenis (Fig. 2-B) using polydioxanone 4/0 (PDS\* II®, Ethicon). The hemipenis was resected distal to the ligature point and the left stump tissue was replaced within the hemipenile sac. The same was repeated on the other hemipenis in the cases of bilateral prolapse. A single ligature could be placed under the base of both hemipenes in the bearded dragons. No need for external suturing or decreasing cloacal diameter with purse-string suture was needed after the hemipenectomy (Fig. 2-C).



**Figure 2: Hemipenectomy in a leopard gecko.**

A – oedematous left hemipenis; B – transfixing suture placed in the base of the hemipenis; C – closure of the corresponding sac after hemipenile resection;

### ***Postoperative care***

All patients received oral *meloxicam* (Meloxidyl®, Ceva) once daily for 5 days in a dose of 0,2 mg/kg as an anti-inflammatory and pain relief agent. If necrotizing tissue changes were established the patients were put under a 10-day course of injectable *enrofloxacin* (Baytril®, Bayer) in a dose of 5 mg/kg every 24 hours. An oleic suspension Combizim® (Veyx-Pharma GmbH) containing *tetracycline hydrochloride*, *neomycin sulfate*, *prednisolone acetate*, and proteolytic enzymes (chymotrypsin, trypsin, papain) was applied topically twice a day for 5 days on the gecko with necrosis of the hemipenile bulge (Fig. 1-C).

## **RESULTS AND DISCUSSION**

The connection between the presence of a prolapse and the type of reptile was described in the literature. Hedley & Eatwell (2014) stated a significant occurrence in chelonians and lizards, rather than snakes, with no considerable difference between the chelonians and the lizards, while other authors (Ramos et al. 2009; Silva et al. 2013) gave the odds mainly to the chelonians. For the study period of the present research were established hemipenile prolapses mainly in lizards as the leopard

gecko was the leading representative, with single cases in snakes and none in chelonians. According to Hedley & Eatwell (2014), the most frequently observed prolapse in the lizards is the one of the hemipenes, which was also confirmed by us.

The most described causes as infection, trauma, or forced separation during mating (Rivera, 2008) were not observed in the present clinical cases, but constipation or fecal impaction as a cause of prolapse of the hemipenis described in lizards (Hedley & Eatwell, 2014) and snakes (Podhade & Harne, 2014) was confirmed. In the anamnesis of all patients, was found evidence of improper nutrition, except in the chameleons. Some lizard species fed exclusively with mealworm larvae have suffered from intestinal compaction (Gauthier & Lesbarreres, 2010), but to our knowledge, there are no published results about leopard geckos. The present study shows such a connection since some of the owners reported prolapse after difficult defecation. An inappropriate diet was observed in the bearded dragon's cases since these agamids need a balanced plant-based diet (Gimmel et al., 2017), but in both of our cases, they were fed mainly with insects. The lack of fiber and hard-shelled insect prey can lead to constipation and irregular defecation in this species (Mans, 2013). In the veiled chameleon and panther chameleon no likely cause could be determined (Hedley & Eatwell 2014), which was also confirmed by our cases.

Our observations showed that the substrate on the terrarium floor was essential and could complicate the hemipenile prolapse. Although not a direct cause of the condition, once prolapsed, sand particles easily stick to the hemipenes. Almost all leopard geckos and bearded dragons in the study were kept on a sand mixture that contributed to the impossibility of retracting the hemipenes and their desiccation. In chameleons, the substrate was not considered as an environmental factor, since they are arboreal species and do not have direct contact with the substrate.

Hemipenile prolapse can be either unilateral or bilateral. No regularity was established about whether one or both hemipenes will permanently evert and no link to the etiological factors influence could be concluded. All patients with surgically removed unilateral prolapse subsequently developed the same on the other hemipenis within 7-14 months, despite the improved environmental conditions and diet. This led us to assume that there are also individual physiological factors in the frequency of hemipenile prolapse, but to our knowledge, the last was not reported by other authors.

The use of an appropriate anesthetic protocol in reptiles is extremely important not only from a humane point of view but also for avoiding stress as a factor. The caudal autotomy is a widespread defensive response of lizards (Lynn et al., 2013), especially in geckos. Although it is not life-threatening it could be an extremely unpleasant outcome.

Intravenous anesthesia is very difficult to achieve in most small lizards, so agents that are effective when administered intramuscularly are preferred in most anesthetic protocols. Dyakova et al. (2019) reported adequate surgical management of unilateral hemipenile prolapse in a panther chameleon by using inhalational anesthesia. From the present study could be concluded that bearded dragons require higher doses of medetomidine and ketamine, than the one reported by Diethelm (2004) and compared to the leopard geckos and chameleons, which was not observed in the available sources. The dose of 0,15 mg/kg for medetomidine and 5 mg/kg for ketamine was not sufficient to reach the required level of anesthesia for hemipenectomy in the bearded dragons. This was also observed in other bearded dragon patients in which we used the same protocol for surgical amputation of tails and toes. Increasing the dose for medetomidine to 0,3 mg/kg and for ketamine to 10 mg/kg

with additional application of local anesthetic led to a sufficient level of anesthesia for short procedures. The induction and recovery time established by the study were similar to those described by Lescano & Quevedo (2016) – for the leopard geckos. No available literature was found regarding the length of the induction in recovery time in bearded dragons and chameleons. The surgical level of anesthesia with the used protocols in the present study was achieved by the 10<sup>th</sup>-12<sup>th</sup> minute in the geckos and chameleons, and by the 25<sup>th</sup>-35<sup>th</sup> minute in the bearded dragons, shown by the lack of cloacal, toe, and tail pinch reflexes. Local block in leopard geckos and chameleons was not used because of their small size and body weight (between 45 and 77 g) and the high risk of intoxication. Although toxic doses for lidocaine infiltration have not been determined in reptiles and it is probably best to use less than 8 mg/kg (Mosley & Mosley, 2015).

Chlorhexidine and povidone solution were preferred for aseptic preparation of the surgical area due to the fact, that the excessive use of alcohol may lead to patient hypothermia due to evaporative heat loss (Alworth et al., 2011). The available sources recommend the use of absorbable monofilament transfixing suture for ligation of the base of the hemipenis to prevent it from slipping away. When possible, the remaining tissue should be short enough to allow the sutured stump to retract into the hemipenile sac and to avoid postoperative exposure trauma (Stahl, 2013). In this way, external sutures are not required and a suture removal procedure is avoided, which decreases the stress levels for lizards. In only one of the presented clinical cases, the authors used two simple interrupted sutures due to the large tissue defect after surgical excision of the necrotic hemipenile bulge. The sutures were kept for 3 weeks. All 16 patients were followed for 3 weeks and no complications were observed in wound healing. During the postoperative examinations, all lizards showed good general condition.

Hemipenectomy is a permanent and suitable solution to everted hemipenes. Even when the manual repositioning is successful, reported data shows a high rate of recurrence – 27% (Hedley & Eatwell, 2014), which was confirmed by our clinical cases. Therefore, our recommendation is for timely surgical amputation, especially if the male lizards are not planned for breeding projects. This will prevent necrotic changes and subsequent infection of the cloacal tissue. The mentioned anesthetic protocol and doses can be applied to short-term surgical procedures in the species described.

## CONCLUSION

The hemipenectomy is an appropriate procedure in hemipenile prolapse and in unilateral cases preserves the patient's fertility without complications. The specific nutrition and husbandry needs of each species are related to the condition and can have preventive character. The medetomidine-ketamine combination is suitable for performing short-term surgery in leopard geckos (*Eublepharis macularius*), veiled chameleons (*Chamaeleo calyptrotus*), panther chameleons (*Furcifer pardalis*) and bearded dragons (*Pogona vitticeps*). Hemipenile prolapse was established to be most commonly found in leopard geckos.

## DECLARATION OF CONFLICTING INTERESTS

The authors declared no potential conflicts of interest for this article's study, authorship, or publication.

## ACKNOWLEDGEMENTS

The presented study was made with the financial support of the National Program “Young Scientists and Postdoctors-2” (NPMUPD-2) – 2023 of the Bulgarian Ministry of Education and Science.

## REFERENCES

1. Alworth, L., S. Hernandez, S. Divers. (2011). *Laboratory reptile surgery: principles and techniques*. Journal of the American Association for Laboratory Animal Science, 50(1), 11-26
2. Andonov, K., N. Natchev, Y. Kornilev, N. Tzankov. (2017). *Does Sexual Selection Influence Ornamentation of Hemipenes in Old World Snakes?* The Anatomical Record, 300(9), 1680-1694
3. Chaprazov, Ts. (2022). *Hirurgia na ekzotichniteivotni*. Eks-pres, Gabrovo, 80-105 (in Bulgarian)
4. Di Girolamo, N. & C. Mans. (2016). *Reptile soft tissue surgery*. Veterinary Clinics: Exotic Animal Practice, 19(1), 97-131
5. Diethelm, G. (2004). *Chemical restraint/anesthetic/analgesic agents used in reptiles*. In “Exotic Animal Formulary”, 3<sup>rd</sup> ed., Elsevier Saunders, 73 – 83
6. Dyakova, Y., I. Krusteva, A. Tyshchenko, Ts. Chaprazov. (2019). *Hemipenile prolapse and hemipenectomy in a Panther Chameleon (Furcifer pardalis)*. Abstract from “21<sup>st</sup> International Veterinary Medicine Students Scientific Research Congress”, April 17-19, 2019, Istanbul, Turkey, 302-303
7. Funk, R. (2002). *Lizard reproductive medicine and surgery*. The veterinary clinics of North America. Exotic animal practice, 5(3), 579-613
8. Gauthier, C. & D. Lesbarreres. (2010). *Growth rate variation in captive species: The case of leopard geckos, Eublepharis macularius*. Herpetological Conservation and Biology, 5(3), 449-455
9. Gimmel, A., H. Kempf, S. Öfner, D. Müller, A. Liesegang. (2017). *Cholelithiasis in adult bearded dragons: retrospective study of nine adult bearded dragons (Pogona vitticeps) with cholelithiasis between 2013 and 2015 in southern Germany*. Journal of animal physiology and animal nutrition, 101, 122-126
10. Govindan, V., L. Annamalai, A. Dasthageer. (2014). *Management of Cloacal Prolapse in a Reticulated Python*. International Journal of Information Research and Review, 1(12), 191-192
11. Hedley, J. & K. Eatwell. (2014). *Cloacal prolapses in reptiles: a retrospective study of 56 cases*. Journal of Small Animal Practice, 55(5), 265-268
12. Holmes, M., O. Putz, D. Crews, J. Wade. (2005). *Normally occurring intersexuality and testosterone induced plasticity in the copulatory system of adult leopard geckos*. Hormones and Behavior, 47(4), 439-445
13. Innis, C. & T. Boyer. (2002). *Chelonian reproductive disorders*. Veterinary Clinics: Exotic Animal Practice, 5(3), 555-578
14. Lescano, J. & M. Quevedo. (2016). *Hemipenile prolapse and hemipenectomy in a leopard gecko (Eublepharis macularius)*. Analecta Veterinaria, 36(2), 5-9
15. Lock, B. (2000). *Reproductive surgery in reptiles*. Veterinary Clinics of North America: Exotic Animal Practice, 3(3), 733-752

16. Lynn, S., B. Borkovic, A. Russell. (2013). *Relative apportioning of resources to the body and regenerating tail in juvenile leopard geckos (Eublepharis macularius) maintained on different dietary rations*. *Physiological and Biochemical Zoology*, 86(6), 659-668
17. Mans, C. (2013). *Clinical update on diagnosis and management of disorders of the digestive system of reptiles*. *Journal of exotic pet medicine*, 22(2), 141-162
18. Martinez-Jimenez, D. & S. Hernandez-Divers. (2007). *Emergency care of reptiles*. *Veterinary Clinics of North America: Exotic Animal Practice*, 10(2), 557-585
19. Mosley, C. I. and Mosley, C. A. (2015). *Comparative anesthesia and analgesia of reptiles, amphibians, and fishes*. In “*Veterinary anesthesia and analgesia: The fifth edition of lumb and jones*”, 5<sup>th</sup> ed., Wiley Blackwell, 784-799
20. Palmer, B., M. Perkins, S. Simon, K. Massie, M. Uribe. (1997). *Reproductive anatomy and physiology: an ecological and evolutionary perspective*. *The biology, husbandry and health Care of Reptiles and Amphibians*, 1, 54-87
21. Podhade, D. & R. Harne. (2014). *Surgical intervention in prolapsed rescued Russell Viper (Daboia russelii)*. *Journal of Wildlife Research*, 2(2), 9-10
22. Ramos, R., D. Vale, M. Hanawo, F. Ferreira, M. Luz, A. Oliveira. (2009). *Penectomia em caso de prolapso peniano em Jabuti-piranga (Geochelone carbonaria) – Relato de caso*. *J Bras Cienc Anim*, 2, 166-74
23. Rivera, S. (2008). *Health assessment of the reptilian reproductive tract*. *Journal of Exotic Pet Medicine*, 17(4), 259-266
24. Silva, K., D. Muniz-da-Silva, K. Silva, V. Garcia, S. Santos. (2013). *Hemipenectomy em Jararaca-Ilhoa (Bothrops insularis) - Relato de Caso*. *Veterinaria e zootecnia*, 20(3), 453-458
25. Stahl, S. (2013). *Paraphimosis*. In: Mayer J., Donnelly T., eds. “*Clinical Veterinary Advisor: Birds and Exotic Pets*”. St. Louis, Elsevier Saunders, 128–130
26. Valdez, J. (2021). *Using Google trends to determine current, past, and future trends in the reptile pet trade*. *Animals*, 11(3), 676-693
27. Vasaruchapong, T. (2014). *Snake Reproductive System*. *Thai Journal of Veterinary Medicine*, 44(Suppl. 1), 89-91
28. Vergilov, V., B. Zlatkov, N. Tzankov. (2017). *Hemipenial differentiation in the closely related congeners Ablepharus kitaibelii (Bibron & Bory De Saint-Vincent, 1833), and Ablepharus budaki Göçmen, Kumlutas, & Tosunoglu, 1996 (Squamata: Sauria: Scincidae)*. *Herpetozoa*, 30(1/2), 39–48

