

## THREE-DIMENSIONAL (3D) ULTRASOUND INVESTIGATIONS FOR MONITORING OF THE SECOND AND THIRD PREGNANCY TRIMESTER IN GOATS

Manol Karadaev<sup>1</sup>, Ivan Fasulkov<sup>1\*</sup>, Nasko Vasilev<sup>1</sup>, Kalin Hristov<sup>2</sup>, Ivan Fedev<sup>3</sup>

<sup>1</sup> Department of Obstetrics, Reproduction and Reproductive Disorders, Faculty of Veterinary Medicine, Trakia University, Stara Zagora, Bulgaria

<sup>2</sup> Department of Surgery, Radiology, Obstetrics and Gynecology, Faculty of Veterinary Medicine, University of Forestry, Sofia, Bulgaria

<sup>3</sup> Student of Veterinary Medicine, Faculty of Veterinary Medicine, Trakia University, Stara Zagora, Bulgaria

\* Corresponding author: [i.fasulkov@gmail.com](mailto:i.fasulkov@gmail.com)

### ABSTRACT

The purpose of this study was to determine the possibility of visualization of fetal and uterine structures in the second and third pregnancy trimester in goats through three-dimensional (3D) ultrasonography. Twenty Bulgarian local goats, aged between 2 and 4 years, weighing 46-52 kg with previously confirmed pregnancy were used in the study. Ultrasound investigations were performed during the 56 - 133 day of pregnancy, at a 2-week interval, via transabdominal approach and an 8.0 MHz linear transducer. Initially, the fetal and uterine structures were visualized in two-dimensional mode (B-mode), and then reconstructed into three-dimensional images using 3D software of the ultrasound machine (SonoScape S2 Vet). The results of this study have shown that 3D ultrasonography is a comparatively easy method to visualize individual parts of the fetus and its internal organs during the second and third pregnancy trimester. At the beginning of the second pregnancy trimester, it was possible visualization and differentiation of 3D ultrasound images of the fetal head and body. At the end of this period (90<sup>th</sup> day of pregnancy) is visualized clear outline of the skull of the fetus, as well as fetal orbit. During the last pregnancy trimester, internal fetal organs such as the forestomachs, kidneys, heart, ribs, etc. were visualized by 3D ultrasound examination. Throughout the study period, clearly 3D images of placentomes were visualized. The analysis of the obtained results shows that three-dimensional (3D) ultrasound examination of the fetal structures in the second and third pregnancy trimester in goats provides an opportunity for detailed observation of individual parts of the body and its internal organs. The resulting clear 3D images of fetal morphological structures can be used as a reference for early detection of embryo-fetal abnormalities.

**Key words:** Ultrasonography, 3D, goats, pregnancy

### INTRODUCTION

In veterinary medicine, the main ultrasound method used for diagnosis and monitoring of pregnancy is two-dimensional ultrasonography (England et al., 1990; Karadaev et al., 2014; Karadaev et al., 2016). In recent years, more researchers are exploring the application of three-dimensional ultrasonography for observation the pregnancy in goats (Kumar et al., 2015), horses (Kotoyori et al., 2012), dogs (Chandolia and George, 2011) and cats (Hildebrandt et al., 2009). Three-dimensional ultrasound is used as a routine method in human obstetric practice for investigation of the embryo-

foetal development and early diagnosis of the foetal abnormalities (Michailidis et al., 2001; Merz and Welter, 2005; Dimitrova et al., 2007).

Three-dimensional (3D) ultrasonography is based on the basic principles used in conventional B-mode (2D) ultrasound. In the two-dimensional ultrasound scans, researcher mentally reconstruct the image in three dimensions, while the three-dimensional ultrasonography using specialized software of the device directly receive information about the third dimension of the research object. When 3D images are presented in real-time, the method is referred to as 4D ultrasonography (Markov and Dimitrova, 2006).

At this stage, the application of 3D ultrasound in veterinary medicine is still rare, due to the high cost of equipment, the need for animal sedation during examination, and the lack of specialized knowledge to perform such research (Chandolia and George, 2011). When performing the scanning, the animals should be in a lateral or backward position and, if possible, under anesthesia as the movement leads to the emergence of additional artifacts. In pregnant animals, it is advisable not to use anesthesia, but only to be well fixed (Chandolia and George, 2011). The few attempts made in small animals with 3D sonography have not produced any concrete results due to the poor quality of the resulting images due to artifacts from respiratory activity during the study. In addition, the software and hardware settings of the ultrasound devices are optimized for human medicine, making it once again difficult to get a high-quality 3D ultrasound image (Hildebrandt et al., 2009). Although in human medicine 3D ultrasonography is well developed and routine research is performed, it is taken as an addition to the conventional two-dimensional ultrasound examination (Bega et al., 2001, Markov et al. 2010).

The purpose of this study was to determine the possibility of visualization of fetal and uterine structures in the second and third pregnancy trimester in goats through three-dimensional (3D) ultrasonography.

## MATERIAL AND METHODS

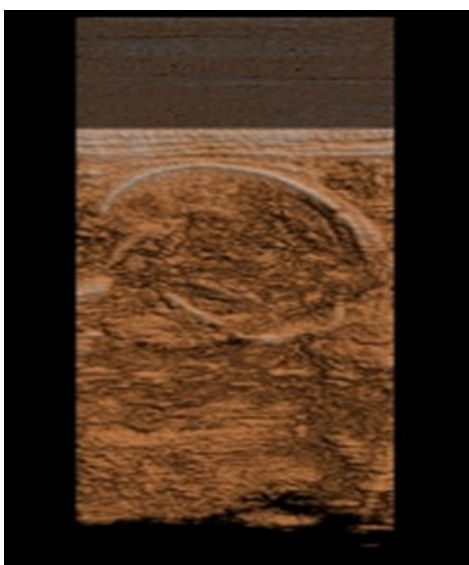
Twenty Bulgarian local goats, aged between 2 and 4 years, weighing 46-52 kg with previously confirmed pregnancy were used in the study. The goats were raised in the Biobase of the Faculty of Veterinary Medicine at Trakia University, Stara Zagora. The diet of goats comprised meadow hay, alfalfa hay and concentrate under the form of pellets composed from corn, wheat, barley, sunflower meal, vitamin and mineral premix, and had free access to water. The investigations were conducted in compliance with the minimum requirements for the protection and welfare of experimental animals and the requirements for the utilization, rearing and/or delivery facilities. Ultrasound investigations were performed during the 56 - 133 day of pregnancy, at a 2-week interval, via transabdominal approach with 8.0 MHz linear transducer in the standing position of the goats. After the hair has been clipped in the left and right ventral abdominal wall, Eco Ultra gel (Milano, Italy) was applied for better contact between the transducer and skin. Initially, the fetal and uterine structures were visualized in two-dimensional mode (B-mode), and then reconstructed into three-dimensional images using 3D software of the ultrasound machine (SonoScape S2 Vet).



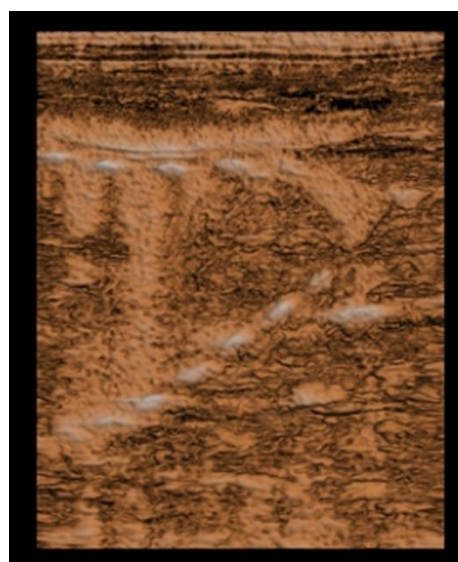
## RESULTS

The results of this study have shown that 3D ultrasonography is a comparatively easy method to visualize individual parts of the fetus and its internal organs during the second and third pregnancy trimester.

At the beginning of the second pregnancy trimester, it was possible visualization and differentiation of 3D ultrasound images of the fetal head (Fig. 1) and body (Fig. 2).

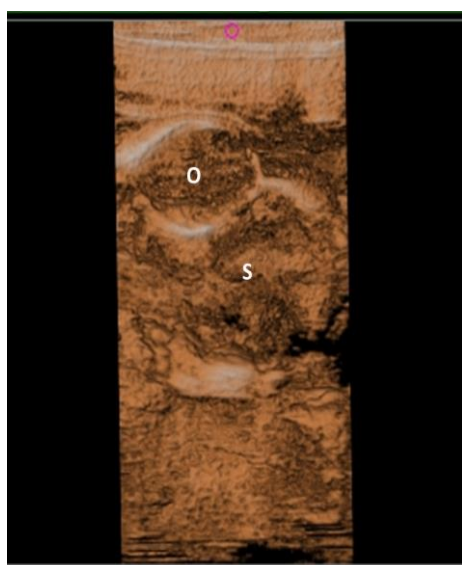


**Fig. 1.** 3D image of the foetal head at 60th day of pregnancy

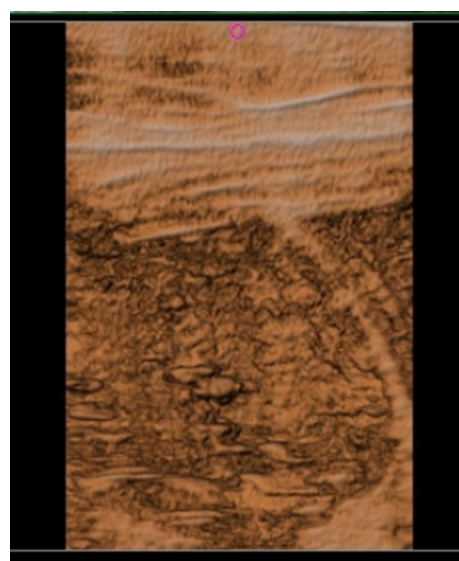


**Fig. 2.** 3D image of the cranial part of foetal body at 60th day of pregnancy

At the end of this period (90th day of pregnancy) is visualized clear outline of the skull of the fetus, as well as fetal orbit (Fig. 3). During the last pregnancy trimester, internal fetal organs such as the forestomachs (Fig. 4), kidneys (Fig. 5), heart and ribs (Fig. 6), etc. were visualized by 3D ultrasound examination. Throughout the study period, clearly 3D images of placentomes (Fig. 7) were visualized.

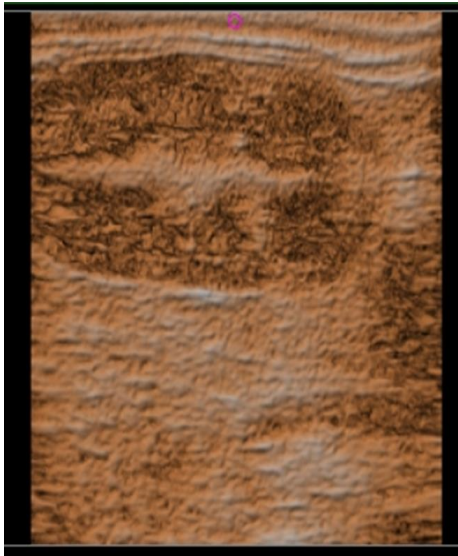


**Fig. 3.** 3D image of the foetal skull (S) and orbit (O) at 90th day of pregnancy

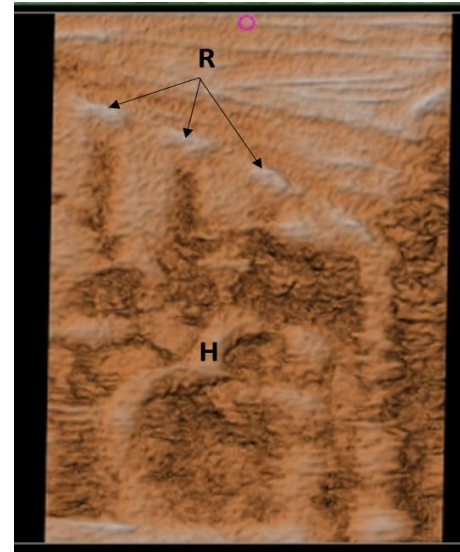


**Fig. 4.** 3D image of the foetal reticulum at 120th day of pregnancy






**Fig. 5.** 3D image of the foetal kidney at 120th day of pregnancy



**Fig 6.** 3D image of the foetal ribs (R) and heart (H) at 120th day of pregnancy



**Fig. 7.** 3D image of placentome at 120th day of pregnancy

## DISCUSSION

The analysis of the obtained results shows that three-dimensional (3D) ultrasound examination of the fetal structures in the second and third pregnancy trimester in goats provides an opportunity for detailed observation of individual parts of the body and its internal organs.

During the different stages of the study period, the three-dimensional image of the bone structures of the fetus was clearly visible. The echogenic cranial bones and the fetal orbit with the hypoehogenic soft tissue structure were clearly observed on the 90<sup>th</sup> day of pregnancy. In the second and third pregnancy trimester, the 3D images of the placentomes were clearly visualized. Some foetal internal organs such as kidneys, forestomachs and heart were also scanned relatively easily and were observed with a clear three-dimensional image during the last pregnancy trimester.



The obtained results are similar with those obtained from Kumar et al. (2015) in Beetal goats. The authors found that after the 76<sup>th</sup> day of pregnancy, the structure of the foetal internal organs was established by both 2D and 3D ultrasound scanning. Other authors also reported similar results in horses (Kotoyori et al., 2012), dogs (Chandolia and George, 2011) and cats (Hildebrandt et al., 2009).

Although the three-dimensional ultrasonography is used in modern human obstetrics for pregnancy monitoring, it is believed to supplement and enhance the diagnostic capabilities of routine 2D ultrasound (Pavlova, 2016). We also consider that the diagnostic value of the 3D ultrasonography in normal pregnancy is close to that of the two-dimensional ultrasound method. Hildebrandt et al. (2009) reported significant difficulties in obtaining a quality image in dogs and cats due to software and hardware problems and the specificity of the study. However, a good 3D image of fetal structures will lead to much more accurate diagnosis in the case of fetal abnormalities.

## CONCLUSION

Our results indicate that 3D ultrasound examinations for monitoring the second and third pregnancy trimester in goats complement the conventional B-mode ultrasonography. The resulting clear 3D images of foetal morphological structures can be used as a reference for early detection of embryo-foetal abnormalities.

## ACKNOWLEDGMENT

This study was supported by the Scientific Research Fund to the Trakia University - Stara Zagora, Bulgaria, Project No 6/2016.

## REFERENCES

1. Bega G., Lev-Toaff A., Kuhlman K., Kurtz A., Goldberg B., Wapner R. (2001). Three-dimensional ultrasonographic imaging in obstetrics: present and future applications. *Journal of Ultrasound in Medicine* 2001: Vol. 20(4): 391-408.
2. Chandolia R. K., George J. (2011). Application of 3D/4D ultrasonography in canine gynaecology and obstetrics. *Indian Journal of Canine Practice* 2011: Vol. 3(2): 99-102.
3. Dimitrova V., Markov D., Dimitrov R. (2007). 3D and 4D ultrasonography in obstetrics. *Akusherstvo i Ginecologija* 2007: Vol. 46(2): 31-40. (BG)
4. England G. C. W., Allen W. E., Porter D. J. (1990). Studies on canine pregnancy using B-mode ultrasound: development of the conceptus and determination of gestational age. *Journal of Small Animal Practice* 1990: Vol. 31: 324-329.
5. Hildebrandt T. B., Drews B., Kurz J., Hermes R., Yang S., Göritz F. (2009). Pregnancy monitoring in dogs and cats using 3D and 4D ultrasonography. *Reproduction in Domestic Animals* 2009: Vol. 44(Suppl. 2): 125-128.
6. Karadaev M., Fasulkov I., Vasilev N., Dimitrov N. (2014). Ultrasound measurements for monitoring of the second and third trimester of gestation in Bulgarian local goats. *Bulgarian Journal of Veterinary Medicine* 2014: Vol. 17(Suppl. 1): 43-44.
7. Karadaev, M., Fasulkov I., Vasilev N., Petrova Y., Tumblev A., Petelov Y. (2016). Ultrasound monitoring of the first trimester of pregnancy in local goats through visualisation and

- measurements of some biometric parameters. *Bulgarian Journal of Veterinary Medicine* 2016: Vol. 19(3): 209-217.
8. Kotoyori Y., Yokoo N., Ito K., Murase H., Sato F., Korosue K., Nambo Y. (2012). Three-dimensional ultrasound imaging of the equine fetus. *Theriogenology* 2012: Vol. 77(7): 1480-1486.
  9. Kumar K., Chandolia R. K., Kumar S., Pal M., Sandeep K. (2015). Two-dimensional and three-dimensional ultrasonography for pregnancy diagnosis and antenatal fetal development in Beetal goats. *Veterinary World* 2015: Vol. 8(7): 835-840.
  10. Markov D., Dimitrova V. (2006). Prenatal diagnosis of structural anomalies of the fetus by 3D/4D ultrasound. *Akusherstvo i Ginecologija* 2006: Vol. 45(Suppl. 3): 32-36. (BG)
  11. Markov D., Pavlova E., Atanasova D., Markov P., Ivanov S. (2010). Prenatal diagnosis of structural abnormalities of the fetus by three-dimensional ultrasound in the first trimester - possibilities and limitations. *Akusherstvo i Ginecologija* 2010: Vol. 49(7): 4-10. (BG)
  12. Merz E., Welter C. (2005). 2D and 3D ultrasound in the evaluation of normal and abnormal fetal anatomy in the second and third trimester in a level III center. *Ultraschall in der Medizin* 2005: Vol. 26: 9-16.
  13. Michailidis G., Economides D., Schild R. (2001). The role of three-dimensional ultrasound in obstetrics. *Current Opinion in Obstetrics and Gynecology* 2001: Vol. 13: 207-214.
  14. Pavlova E. (2016). Clinical application of three-dimensional ultrasound in obstetrics. PhD thesis, Sofia, p. 152. (BG)

