

TWO CASES OF ECTOPIC ABDOMINAL PREGNANCY IN QUEENS

Marina Ivanova¹, Cvetelina Ivanova², Todor Marinkov¹, Plamen Georgiev^{2*}

1. Four Paws Bulgaria;
2. Department of Obstetrics, reproduction and reproductive disorders, Faculty of Veterinary Medicine, Trakia University, Stara Zagora, Bulgaria,
3. Department of Surgery, Radiology, Obstetrics and Gynecology, Faculty of Veterinary Medicine, University of Forestry, Sofia, Bulgaria

* Corresponding author: plana@mail.bg

ABSTRACT

Extrauterine pregnancy (or ectopic) pregnancy, is a rare condition, when embryos or fetuses are located outside the uterus. The objective of this work was to describe two cases of abdominal ectopic pregnancy found during a routine spay of stray cats. Before surgery in both animals abdominal enlargement was detected. Fetuses were located in the abdominal cavity, covered adhesiv by omentum, with no clear traces of fetal membranes. In the first cat 3 and in the other 2 deformed fetuses in size from 3 to 6 cm were found. In the second animals the fetal limbs and head were completely formed. Bones ossification was visualized by X-ray. The uterus size in queens were same during a non-pregnant state without visible external changes. After neutering animals recovered quickly. The second operation was performed more than three months after the end of the breeding season. It was assumed that the described clinical cases were refer to secondary abdominal pregnancy. They are evidence that ectopic pregnancy in cats can be detected not only as an accidental finding but also by assumption of prolonged pregnanc.

Key words: cat, ectopic pregnancy, fetuses

INTRODUCTION

The extrauterine pregnancy, also called ectopic, is a pathological state when the embryos or fetuses can be located and even develop outside the uterus. It is mainly divided into two types - primary, when the fertilised oocyte attach itself to the uterine tube, peritoneum, omentum, liver, spleen, or onto the outside part of the uterus (Dzięcioł et al., 2012) and secondary, when after initial development in the uterus, the fetus falls into the abdominal cavity (Corpa, 2006; Rosset et al., 2011). According to many authors (Corpa, 2006; Mirsepehr et al., 2015; Zheng et al., 2018), tubular and abdominal ectopic pregnancies are most common.

As pathology in humans ectopic pregnancy was known over 900 years ago (Buckley and Caine, 1979; Corpa, 2006). It was one of the major causes of maternal death during the first trimester of pregnancy, causing mortality rate of 3 per 1000 cases (De Cecco et al., 1984). Afterward this condition has undergone a increase (Wolfman and Holtz, 1983), although the ectopic pregnancy rate actually was seemed to be stabilized (Van Den Eeden et al., 2005). Ectopic pregnancy is rarely diagnosed in veterinary medicine (Rosset et al., 2011).The exception is the cat (Mirsepehr et al., 2015; Zheng et al., 2018). So far there are no published data about ectopic pregnancy in cats in Bulgaria.

The objective of this work was to document and describe two cases of abdominal extrauterine pregnancy which were established within two months during routine neutering of cats.

DESCRIPTION OF CLINICAL CASES

Two European shorthair cats were operated in the clinic of the Four Paws Foundation in Sofia, as part of a program for castration of stray animals. When the animals were brought to the clinic, their general condition and nutritional status were normal. They were in contact with people who cared for them and reported most general anamnestic data. Before surgery abdominal enlargement in animals was detected.

For induction of anesthesia in patients we used a combination of xylasini hydrochloridum and tiletamine-zolazepam. For this purpose, 10 ml of a solution of Xylasini hydrochloride containing 0.2 g active substance (Xylazin® Bioveta Czech Republic, 50 ml 2%) is added to a vial containing 0.125 mg of Tiletamine HCl and 0.125 mg of Zolazepam HCl (Zoletyl® 50 Virbac France). The resulting solution was administered intramuscularly at a dose of 0.1 ml/kg m.

The first cat was operated on September 27, 2017. Its reproductive status and age were not known. In general, it was obviously a young animal about 3 years old and weighing 3.2 kg. After laparotomy in the abdominal cavity, 3 deformed mummified fetuses with a size of about 3 cm were found. The fetal bone system was well developed.

The second cat was operated on December 5, 2017. According the history her age was 4 years and 7 months. Up to this point the disturbance in general condition was not detected. The cat was not dewormed and vaccinated. She gave birth 3 times. In the last month an animal has increased its appetite. Its stomach has grown. Her condition was good, with a body weight of 4.2 kg. After a median laparotomy in the abdominal cavity, two mummified fetuses with a solid consistency, well-formed limbs and head were found (Fig. 1). The dimensions of one was 6 × 3,5 cm, the other was deformed and a size of 5 × 4,5 cm.

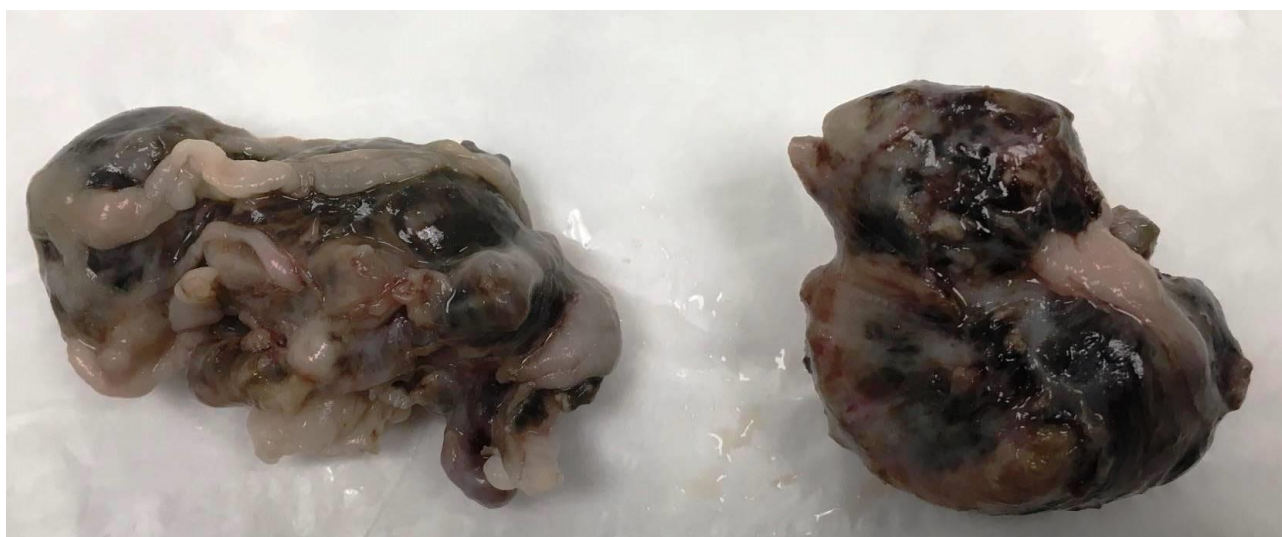


Fig. 1 In the second cat two mummified fetuses with a solid consistency and well-formed limbs and head were found. The dimensions of one were 6 × 3,5 cm, the other was deformed and had a size of 5 × 4,5 cm

In both animals fetuses were tightly surrounded by omentum (Fig. 2). In some places we found whitish adhesions and thickened areas that we could define as remnants of fetal membranes and placenta. After removal of parts of the omentum, we found that hair was better formed in the fetuses of the second cat. Fetuses were preserved in a 4% formaldehyde solution. Later in the Small animal clinic of the Faculty of veterinary medicine at Thracian University was performed X-ray through which the complete development of all bones was established (Fig. 3).

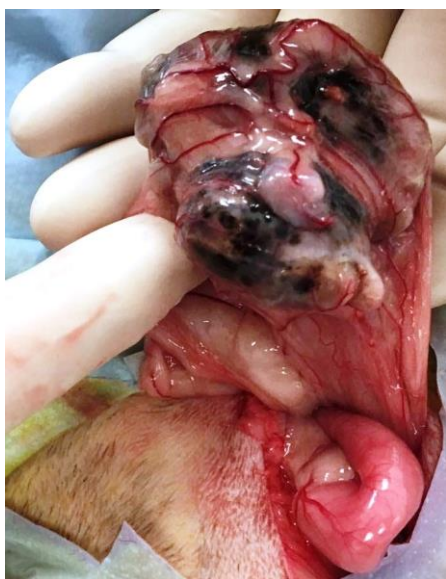

Fig. 2 Ectopic fetuses in the second cat. The fetuses were tightly surrounded by omentum

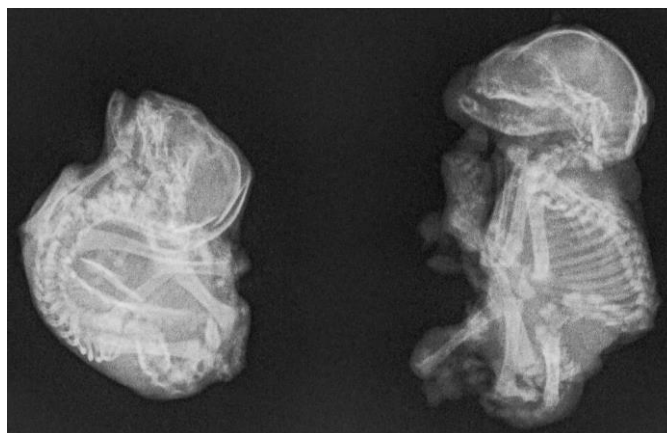

Fig. 3 X-ray examination of fetuses in second cat. The complete development of all bones could be established.

Ovariohysterectomy was performed according to the method described by Brass (1999). The uteri of cats were small, normal sized, smooth surface, pink, without trace of trauma, adhesion or cicatrices. In both animals the surgical intervention performed without complications. After 24 hours of stay at the station, the queens were released in good condition. On the twelfth day the animals were brought for a prophylactic examination in which no pathological deviations in the healing process were found.

DISCUSSION

In contrast to primates, rodents and lagomorphs species that possess a discoid hemochorial placenta facilitating the development of primary ectopic pregnancy, there is a lack of scientific evidence for presence of primary extrauterine pregnancy in another domestic animals (Smith et al., 1989; Corpa, 2006; Dzięcioł et al., 2012). Given our findings, it can be assumed that the described clinical cases are refer to secondary abdominal ectopic pregnancy.

This condition occurs when the fetuses together with the placenta (Lederer and Fisher, 1960; Corpa, 2006) enter into the abdominal cavity due to the rupture of the uterine wall, which usually results from an external trauma, jump or abnormalities (Chong, 2017; Singhal et al., 2017). Typically the fetuses coated with the omentum and the fetal membranes attached at a certain place, but shortly thereafter they die (Rosset et al., 2011; Zheng et al., 2018). Post-mortem changes include dehydration, deformation and shortening of fetuses, disintegration of the fetal membranes and adhesion to a surface to surrounding tissues. Although in the literature exist similar patients, questions related to the precise causes and mechanisms leading to this condition in animals remain largely unexplained.

Considering the size of the fetuses and the degree of their development, it was obvious that the normal course of pregnancy has been disturbed in its final stages. Evidence of this are the full formation of bone and stage of hair development (Knospe, 2002). According to Wehrend (2016) special form of secondary abdominal pregnancy is fetal removal due to uterine rupture during the birth. According to the author, this is not a true ectopic pregnancy. We assume that in the second cat, such a condition can not be completely excluded.

The animals described in this publication live in natural light regime. It is well known that in the conditions of Bulgaria the breeding season ends at the end of summer. The presence of fetuses in early December is an evidence to the fact that they have stayed dead in the abdomen at least for a month. The exact mechanisms that lead to its preservation is not clear.

The uterus size in our queens were like this of non-pregnant animals without visible external changes. It is assumed that despite of the rupture a complete recovery is possible. The logical questions that arise in this regard are about size of the uterine rupture, the mechanism of evacuation of the fetuses and the placenta, of course, full repair of uterine wall.

According to most authors, ectopic pregnancy in animals is asymptomatic and fetuses are detected accidentally (Corpa, 2006; Rosset et al., 2011; Breka and Kvakan, 2012). Diagnosis is mainly due to X-ray, ultrasound and laparotomy (Eddey 2012; Mirsepehr et al., 2015).

Ectopic fetuses are usually aseptic (Mirsepehr et al., 2015) but nevertheless, this condition may occur occasionally with symptoms as vomiting, anorexia, lethargy, haematuria, pollakisuria, etc., (Johnston et al., 2013). Symptoms resembling dystocia may be detected. It is not known whether ectopic fetuses are the direct cause of certain clinical signs or observed clinical symptoms are the result of initial rupture of the uterus, secondary bacterial contamination and absorption of biologically active substances (Dzięcioł et al., 2012). According to Bostedt (2016), the worsening of the general condition of the cat occurs as a result of extensive adhesions that disrupt the function of organs in the abdominal cavity. The overall condition of cats that have been used to study, was good, and even within the last month, second cat had an increased appetite. Treatment for ectopic pregnancy is operative. It involves the removal of fetal tissues and the adjacent accompanying structures (Johnston et al., 2013; Mirsepehr et al., 2015).

Two described cases are confirmation of the existence of abdominal ectopic pregnancy in the cats. The lack of complications in our queens demonstrates good tolerance of this species towards the ectopic pregnancy. It can be detected not only as an accidental finding but also by assumption of prolonged pregnancy.

REFERENCES

1. Bosted H. (2016). Extruterine Gravidität. In: Reproduktionsmedizin bei Hund und Katze, ed. Anne-Rose Günzel-Apel, Hartwig Bostedt, Schattauer, pp. 496-498.
2. Brass W. (1999). Ovar und Uterus. In: H. Schebitz U. W. Brass (Hrsg.): Operationen an Hund und Katze. 2. Aufl., Parey Buchverlag, Berlin, pp. 273-277
3. Breka St., Kvakan I. (2012). Ektopiena gravidnost u macke prikaz slueaja. Veterinarska Stanica: Vol. 43(1): 81-85.
4. Buckley P., Caine A. (1979). A high incidence of abdominal pregnancy in the Djungarian hamster (*Phodopus sungorus*). Journal of Reproduction and Fertility: Vol. 56: 679-682.
5. Chong A. (2017). A case of feline ectopic abdominal fetuses secondary to trauma. The Canadian Veterinary Journal: Vol. (58): 400-402.
6. Corpa J. M. (2006). Ectopic pregnancy in animals and humans. Reproduction: Vol. (131): 631-640.
7. De Cecco L., Capitanio G. L., Croce S., Forcucci M., Gerbaldo D., Rissone R. (1984). Biology of nidation and ectopic implantation. Acta Europaea Fertilitatis: Vol. 15: 347-355.
8. Dzięcioł M., Niżański W., Ochota M., Błasiak K, Kozdrowski R, Stańczyk E, Twardoń J. (2012). Two separate cases of extrauterine pregnancy in queens. Electronic Journal of Polish Agricultural Universities: Vol. 15 (2).
9. Eddey P. D. (2012). Ectopic pregnancy in an apparently healthy bitch. Journal of the American Animal Hospital Association: Vol. 48(3): 194-197.
10. Lederer H. A., Fisher L. E. (1960). Ectopic pregnancy in a dog. Journal of the American Veterinary Medical Association: Vol. (137): 61.

11. Mirsepehr P., Asheghian I., Hajinasrollah M., Javadi S. R., Bashiri A. R., Esmailinejad M. R., Taghipour H., Mojtahedzade S. M. (2015). Accidental Finding of Ectopic Pregnancy in a Cat with Presence of Three Fetuses without Gestational Sac that were Attached to the Abdominal Wall and Mesentery (A Case Report). *International Journal of Advanced Biological and Biomedical Research*: Vol. 3 (3): 217-221
12. Knospe C. (2002). Periods and Stages of the Prenatal Development of the Domestic Cat, *Anatomia, Histologia, Embryologia*: Vol. (31): 37-51
13. Rosset E., Galet C., Buff S. (2011). A case report of an ectopic fetus in a cat *Journal of Feline Medicine and Surgery*: Vol. 13 (8): 610-613.
14. Smith C. A., Stone D. M., Prieur D. J. (1989). Spontaneous profuse superovulation in association with ectopic fetuses in a rabbit. *Laboratory Animal Science*: Vol. (39): 74-77.
15. Singhal S., Ahuja A. K., Shivkumar, Dhindsa S. S., Singh, A.K. (2017). Uterine Rupture and Ectopic Pregnancy in a Bitch: A Special Case. *International Journal of Pure & Applied Bioscience*: Vol. 5(5): 641-643.
16. Van Den Eeden S. K., Shan J., Bruce C., Glasser M. (2005). Ectopic pregnancy rate and treatment utilization in a large managed care organization. *Obstetrics and Gynecology*: Vol. (105): 1052-1057.
17. Wolfman W., Holtz G. (1983). Update on ectopic pregnancy. *Canadian Medical Association Journal*: Vol. (129): 1265-1269.
18. Wehrend A. (2016). Extrauterin gravidität. In: *Reproduktionsmedizin bei Hund und Katze*, ed. Anne-Rose Günzel-Apel, Hartwig Bostedt, Schattauer, pp. 280-281.
19. Johnston S. D., Harish G., Stevens J. B., Scheffler H. G. (2013). Ectopic pregnancy with uterine encapsulation in a cat. *Journal of the American Veterinary Medical Association*: Vol. 183 (9): 1001-1002.
20. Zheng J. S., Wang Z., Zhang J. R., Qiu S., Wei RY., Nie J., Zhu TT. (2018). Ectopic Pregnancy in Two Cats. *Acta Scientiae Veterinariae*: Vol. 46 (Suppl 1): 257.

