

## THREE-DIMENSIONAL ULTRASONOGRAPHY OF THE MAMMARY GLAND IN LACTATING COWS

Ivan Fasulkov<sup>1\*</sup>, Manol Karadaev<sup>1</sup>, Nasko Vasilev<sup>1</sup>,  
Martin Nikolov<sup>2</sup>, Tsvetelin Nonov<sup>2</sup>

<sup>1</sup> Department of Obstetrics, Reproduction and Reproductive Disorders, Faculty of Veterinary  
Medicine, Trakia University, 6015 Stara Zagora, Bulgaria

<sup>2</sup> Students of Veterinary Medicine, Faculty of Veterinary Medicine, Trakia University,  
6015 Stara Zagora, Bulgaria

\* Corresponding author: [i.fasulkov@gmail.com](mailto:i.fasulkov@gmail.com)

### ABSTRACT

The purpose of this study was to investigate the possibility of visualization and characterization of the mammary glands structures in lactating cows through 3D ultrasonography. Ten Black-and-white cows, 5 years of age, weighing 380-450 kg, were included in the experiment. The cows were reared in the cattle barn of the Experimental Farm of the Trakia University – Stara Zagora. The animals were in third lactation, between the 2nd and 4th months of lactation. Ultrasound examinations of the mammary gland was made through transcutaneous approach with linear transducer at a frequency of 10.0 MHz. The 3D sonography at the top of the teat was characterized by a clear visualization of the morphological structures papillary orifice, teat canal and rosette of Furstenberg. Above them, in the three-dimensional image were differentiated three-layer construction of the teat wall, as well as milk in the teat cistern. At the boundary between teat and gland cistern of the mammary gland, as clear rounded structures in 3D images were visualized vessels of the Furstenberg's venous ring. When examining the body of the udder, three-dimensional ultrasonography allowed characterization of lactiferous ducts in gland cistern and normal mammary parenchyma. Our results indicate that 3D ultrasonography of the mammary gland in dairy cows allows detailed imaging of the morphological structures located therein. This will lead to more accurate diagnosis and prognosis in cases of pathological changes localized in teat and mammary parenchyma of the udder.

**Key words:** Ultrasonography, 3D, mammary gland, cows

### INTRODUCTION

Three-dimensional ultrasonography is a relatively new method for ultrasound examination in obstetrics and gynecology. The first studies on the application of the method are related to the visualization of normal fetal structures and prenatal diagnosis of congenital fetal abnormalities (Steiner et al., 1994; Blaas et al., 1995; Merz et al., 1995). In a classical two-dimensional ultrasonographic examination, the object under investigation is scanned in different oriented and intersecting planes. In this way, two-dimensional images are obtained on the monitor, which the operator mentally reconstructs and receives a virtual image of three-dimensional objects (Dimitrova et al., 2007). In three-dimensional ultrasound, image reconstruction is performed by the software of the ultrasound machine and the processed signals are presented to the monitor as a real three-dimensional image (Bonilla-Musoles et al., 2000; Pretorius et al., 2003; Dimitrova et al., 2007).

In human medicine, a number of authors have demonstrated the advantages of the method in examining physiological and pathological conditions of the mammary gland (Kotsianos et al., 2005; Weismann and Hergan, 2007; Weismann et al., 2011). The main advantage of three-dimensional sonography compared to other methods of ultrasound examination of reproductive organs and mammary gland may be the possibility of visualization of morphological structures and pathological changes in views and inclined planes, which can not be represented by other methods (Franz et al., 2006).

There are few studies on the use of 3D ultrasonography in veterinary medicine, mainly focused on the investigation of embryo-fetal development in bitches (Hildebrandt et al., 2009; Chandolia and George, 2011), mares (Kotoyori et al., 2012) and goats (Kumar et al., 2015).

There are very few data on the application of this method for ultrasound examination of the udder (Franz et al., 2004; Franz et al., 2006; Franz et al., 2009).

The purpose of this study was to investigate the possibility of visualization and characterization of the mammary glands structures in lactating cows through 3D ultrasonography.

## MATERIAL AND METHODS

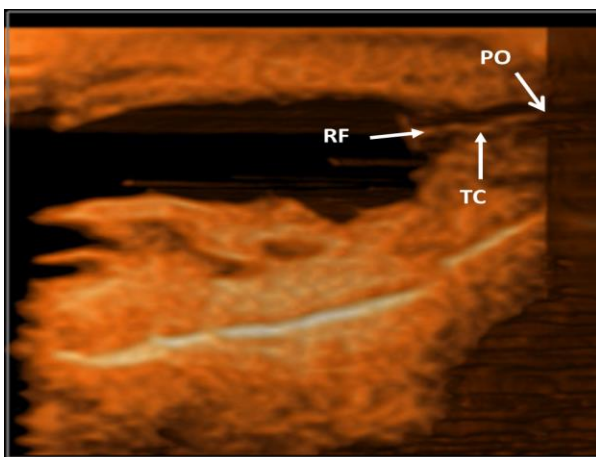
Ten Black-and-white cows, 5 years of age, weighing 380-450 kg, were included in the experiment. The cows were reared in the cattle barn of the Experimental Farm of the Trakia University – Stara Zagora. The animals were in third lactation, between the 2nd and 4th months of lactation.

Ultrasonographic studies were done with SonoScape S2Vet ultrasound machine (SonoScape, China). Ultrasound examinations of the mammary glands structures were made through transcutaneous approach with linear transducer at a frequency of 10.0 MHz. Ultrasonic gel (Eco Ultra gel, Milano, Italy) was applied for better contact between the transducer and udder skin.

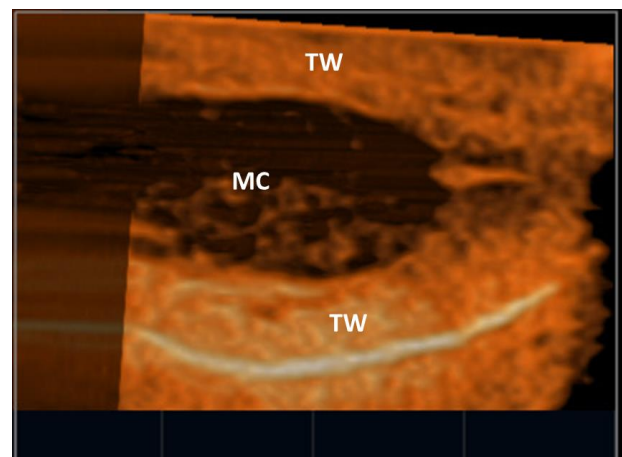
Mammary gland structures were initially seen in a two-dimensional image. After freezing the two-dimensional image, it was reconstructed into a three-dimensional image by the software of the ultrasound apparatus.

## RESULTS

The 3D sonography at the top of the teat was characterized by a clear visualization of the morphological structures papillary orifice, teat canal and rosette of Furstenberg (Figure 1). Above them, in the three-dimensional image were differentiated three-layer construction of the teat wall, as well as milk in the teat cistern (Figure 2).



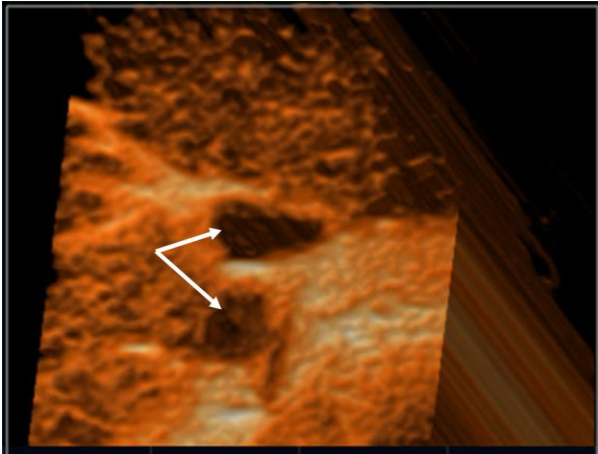
**Figure 1.** 3D image of the teat: PO – papillary orifice; TC – teat canal; RF – rosette of Furstenberg



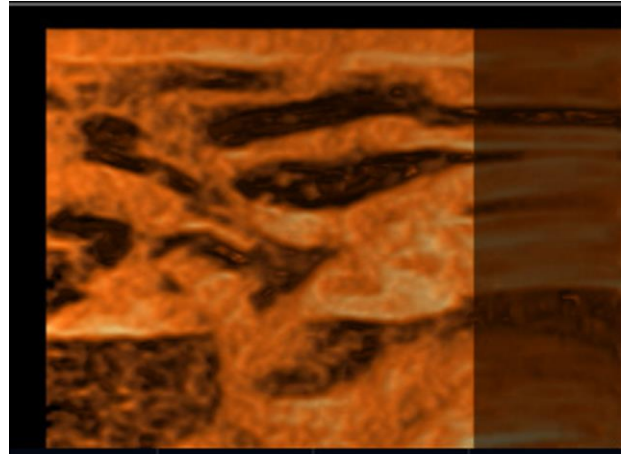
**Figure 2.** 3D image of the teat cistern: TW – teat wall; MC – milk cistern

At the boundary between teat and gland cistern of the mammary gland, as clear rounded structures in 3D images were visualized vessels of the Furstenberg's venous ring. (Figure 3).

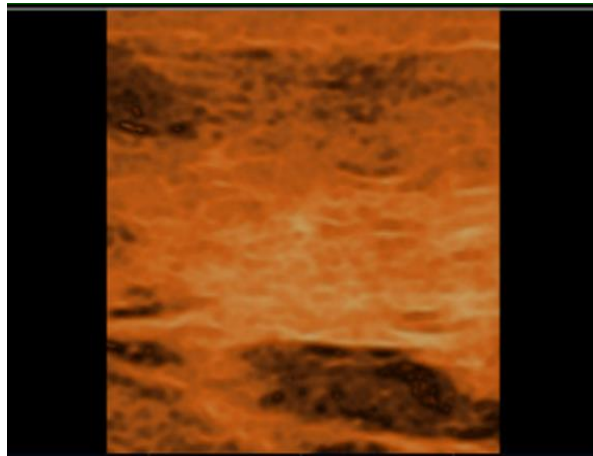
When examining the body of the udder, three-dimensional ultrasonography allowed characterization of lactiferous ducts in gland cistern (Figure 4) and normal mammary parenchyma (Figure 5).



**Figure 3.** 3D image of the Furstenberg's venous ring (white arrows)



**Figure 4.** 3D image of the lactiferous ducts in gland cistern



**Figure 5.** 3D image of the mammary parenchyma

## DISCUSSION

Three-dimensional ultrasonography is based on the basic principles used in conventional B-mode ultrasound as through the specialized software of the device directly obtain information about the third dimension of the subject.

The application of 3D ultrasound in veterinary practice is relatively limited. The main reasons for this could be the high cost of equipment, probably the need for patient anesthesia during examination, and the lack of specialized knowledge to carry out such research (Chandolia and George, 2011). Experiments that have been performed on dogs have not produced any concrete results. The resulting 3D images were of poor quality due to artifacts arising from the patient's respiratory movements during the study. In addition, the software and hardware settings of the devices are optimized for human medicine, making it more difficult to get a high-quality 3D image (Hildebrandt et al., 2009). Although in human obstetrics and gynecology 3D ultrasonography is developed as a routine examination of fetal morphology, the method is accepted as a complement to conventional two-dimensional ultrasound (Bega et al., 2001).

The analysis of our results shows that 3D images of mammary glands in lactating cows have very high image quality and the possibility of their detailed observation in depth. The investigations carried out by Franz et al. (2006) show that when applied to the teat, 3D ultrasonography does not

seem to be less or more helpful than other diagnostic imaging techniques. However, we believe that in the area of the teat it was clearly possible to visualize in a quality three dimensional image the structures papillary orifice, teat canal, rosette of Furstenberg, teat wall and teat cistern.

Similar to the results reported by Franz et al. (2004), the quality of the 3D images that we received gave an opportunity for detailed observation of the studied morphological structures, because 3D images can be shifted or rotated around three axes in any plane. This will lead to a precise comparison with pathological changes that may occur in the teat.

The 3D ultrasound examination of the udder in lactating cows allowed a detailed representation of the mammary parenchyma and lactiferous ducts. To a large extent, the good quality of the resulting 3D image was also determined by the probe frequency used in the initial 2D scan. In support of this statement, Franz et al. (2006) report the production of a good 3D image of the teat cistern, the rosette of Furstenberg and the teat canal using a 10.0 MHz linear transducer.

Summarizing our results it may be argued that in order to obtain a qualitative and detailed three-dimensional visualization of the mammary gland structures in lactating cows, the 3D software of the ultrasound device is paramount. As inconvenience of the method under field conditions could indicate delays in the reconstruction of two-dimensional images into three-dimensional. However, this can be avoided by using a 4D (real-time 3D) ultrasonography that will be the subject of our future research.

## CONCLUSION

Our results indicate that 3D ultrasonography of the mammary gland in dairy cows allows detailed imaging of the morphological structures located therein. This will lead to more accurate diagnosis and prognosis in cases of pathological changes localized in teat and mammary parenchyma of the udder.

## ACKNOWLEDGMENT

This study was supported by the Scientific research Fund to the Trakia University - Stara Zagora, Bulgaria, Project No 8/2015.

## REFERENCES

1. Bega G., Lev-Toaff A., Kuhlman K., Kurtz A., Goldberg B., Wapner R. (2001). Three-dimensional ultrasonographic imaging in obstetrics: present and future applications. *Journal of Ultrasound in Medicine* 2001: Vol. 20(4): 391-408.
2. Blaas H. G., Eik-Nes S. H., Kiserud T., Berg S., Angelsen B., Olstad B. (1995). Three-dimensional imaging of the brain cavities in human embryos. *Ultrasound in Obstetrics & Gynecology* 1995: Vol. 5(4): 228-232.
3. Bonilla-Musoles F., Machado L. E., Osborne N. G. (2000). Three-dimensional ultrasound for the new millenium: text and atlas. *Aloka, Madrid*, pp. 9-20.
4. Chandolia R. K., George J. (2011). Application of 3D/4D ultrasonography in canine gynaecology and obstetrics. *Indian Journal of Canine Practice* 2011: Vol. 3(2): 99-102.
5. Dimitrova V., Markov D., Dimitrov R. (2007). 3D and 4D ultrasonography in obstetrics. *Akusherstvo i Ginecologiiia* 2007: Vol. 46(2): 31-40.
6. Franz S., Floeck M., Hofmann-Parisot M. (2009). Ultrasonography of the bovine udder and teat. *Veterinary Clinics of North America: Food Animal Practice* 2009: Vol. 25: 669-685.
7. Franz S., Hofmann-Parisot M., Baumgartner W. (2004). Evaluation of three-dimensional ultrasonography of the bovine mammary gland. *American Journal of Veterinary Research* 2004: 65(8): 1159-1163.
8. Franz S., Hofmann-Parisot M., Baumgartner W. (2006). 3D-sonographie beim rind: darstellung der zitzenstrukturen. *Tierärztliche Praxis* 2006: Vol. 34(G): 73-79.





9. Hildebrandt T. B., Drews B., Kurz J., Hermes R., Yang S., Göritz F. (2009). Pregnancy monitoring in dogs and cats using 3D and 4D ultrasonography. *Reproduction in Domestic Animals* 2009: Vol. 44(Suppl. 2): 125-128.
10. Kotoyori Y., Yokoo N., Ito K., Murase H., Sato F., Korosue K., Nambo Y. (2012). Three-dimensional ultrasound imaging of the equine fetus. *Theriogenology* 2012: Vol. 77(7): 1480-1486.
11. Kotsianos D., Wirth S., Fischer T., Hiltawsky K., Sittek H., Reiser M. (2005). 3D ultrasound (3D US) in the diagnosis of focal breast lesions. *Der Radiologe* 2005: Vol. 45(3): 237-244.
12. Kumar K., Chandolia R. K., Kumar S., Pal M., Sandeep K. (2015). Two-dimensional and three-dimensional ultrasonography for pregnancy diagnosis and antenatal fetal development in Beetal goats. *Veterinary World* 2015: Vol. 8(7): 835-840.
13. Merz E., Bahlmann F., Weber G. (1995). Volume scanning in the evaluation of fetal malformations: a new dimension in prenatal diagnosis. *Ultrasound in Obstetrics & Gynecology* 1995: Vol. 5(4): 222-227.
14. Pretorius D. H., Nelson T. R., James G. (2003). Three-dimensional ultrasound in obstetrics. In: Nyberg D. A., McGahan J. P. (eds.), *Diagnostic imaging of fetal anomalies*. Lippincott Williams & Wilkins, Philadelphia, pp. 969-988.
15. Steiner H., Gregg A. R., Bogner G., Graf A. H., Weiner C. P., Staudach A. (1994). First trimester three-dimensional ultrasound volumetry of the gestational sac. *Archives of Gynecology and Obstetrics* 1994: Vol. 255(4): 165-170.
16. Weismann C., Hergan K. (2007). Current status of 3D/4D volume ultrasound of the breast. *Ultraschall in der Medizin* 2007: Vol. 28(3): 273-282.
17. Weismann C., Mayr C., Egger H., Auer A. (2011). Breast sonography - 2D, 3D, 4D ultrasound or elastography? *Breast Care (Basel, Switzerland)* 2011: Vol. 6(2): 98-103.

